

## Advanced Techniques in 4D Ultrasound: Fly Thru

Edward G. Grant, MD, FACR, Professor and Chairman

Department of Radiology, University of Southern California, Keck School of Medicine

Ultrasound is a fast, non-invasive imaging technology often used as a first-line diagnostic exam, providing clinicians the ability to diagnose disease quickly and develop treatment plans. Recent advancements in 3D and 4D ultrasound continues to expand clinical applications, and the introduction of Toshiba's Aplio™ 500 ultrasound system offers exciting new capabilities.

Toshiba's Aplio 500 ultrasound system enables clinicians to diagnose disease in new ways, using the most advanced visualization tools in the industry. The system combines advanced imaging capabilities, workflow automation tools and superior ergonomics for more accurate diagnoses and improved departmental efficiency.

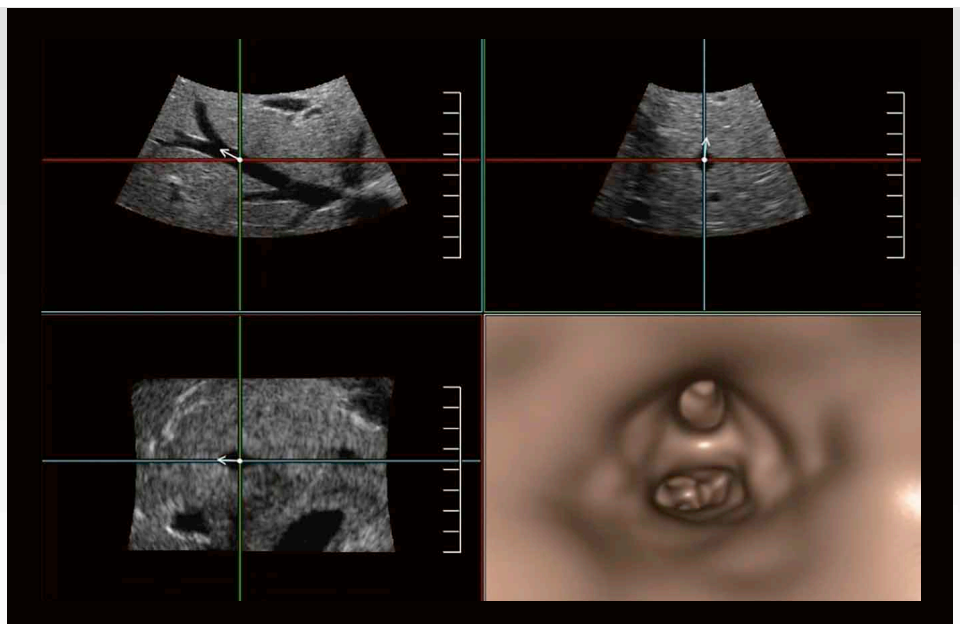
One of these advanced features is Toshiba's Fly Thru technology, an industry first using 4D ultrasound to "fly through" interiors of ducts and vessels for better exploration of lesions and masses and in communication when planning interventional procedures. Fly Thru gives a new perspective of 4D imaging, namely, looking from the inside out. This technology and the images it produces are unlike anything previously found in the ultrasound world. It truly represents a completely unique method of processing ultrasound images and a unique way of looking at structures within the body.

### Fly Thru: A New Perspective

The engineers who developed the technology refer to this as "perspective imaging" because it produces

a different perspective in the way clinicians view various structures. Fly Thru's images virtually travel through a body cavity and are very similar to those produced by CT virtual colonoscopy. Fly Thru enables sonographers and physicians to interrogate anatomy from views never before seen in ultrasound, bringing a whole new dimension to the modality.

Typical 4D imaging uses a parallel projection so one's viewpoint is essentially endless, however this creates difficulties in seeing depth or what is around the anatomy being imaged. Fly Thru is different from traditional 4D imaging, as it uses perspective projection, where the image is displayed exactly as if you were doing an endoscopic procedure.



When using the Aplio 500 in practice, there are various ways to perform Fly Thru. First, the system itself will automatically navigate through the structure, moving the observer's eye according to the center line of the blood vessel, intestinal tract, mammary duct or any other fluid-filled structure in the body. In this "auto" mode, the system passes through the tubular structure while deciding automatically which branch to follow, for example, through the branches of the portal vein.

The second option is conducting manual Fly Thru navigation, which is useful depending on what is being imaged. In manual mode clinicians direct the arrow, or perspective line of sight, through the structure. For example, in manual navigation when viewing a bifurcating vessel, there is the ability to choose which of the two vessels to inter-

rogate. Likewise, when looking at a polyp in the endometrium, clinicians can view from behind it and investigate another perspective. These two options for both automatic and manual mode provide flexibility in using Fly Thru for various clinical applications.

In addition to automatic and manual visualization modes, Fly Thru's features make it easy to use. The Aplio 500 has rapid reconstruction time and the ability to store the ultrasound volume directly on the unit, allowing images to be viewed after the examination is complete. There is also an overview mode to look at fluid-filled bowel loops or pelvic structures, like the uterus, when they are surrounded by fluid. With overview mode, clinicians can also manipulate the image and view different parts for expanded clinical applications.

Fly Thru images are also acquired like any other normal 3D data set – the Fly Thru mode is pressed, the arrow is pointed in the direction or at the structure being imaged and Fly Thru begins. There is a slight learning curve for the manual navigation mode, but overall it is a very easy technology to use.

**Potential Clinical Applications**

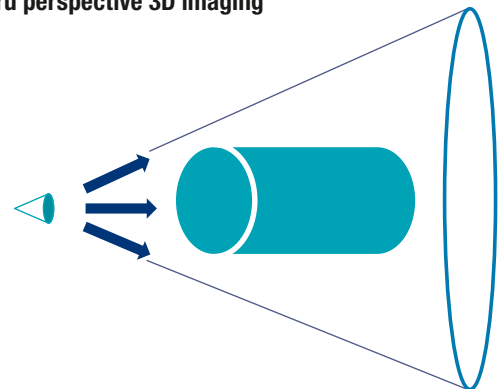
The images produced using Fly Thru are extraordinary, and as a new technology, the clinical applications are just beginning to be explored. The first potential clinical application we foresee is imaging of the endometrium. The endometrium is a solid structure, but if it is distended with fluid, as in the case of a saline hysterosonogram, Fly Thru enables a virtual hysteroscopy. This is a new way of viewing polyps, myomata, synechiae or anything that is in the middle of the endometrial canal. Fly Thru is

**Conventional 3D imaging**



Conventional 3D Imaging makes use of parallel projection to display the surface of a given structure.

**Fly Thru perspective 3D imaging**



Fly Thru uses perspective projection to display the surface structure, emphasizing the near field over the far field.

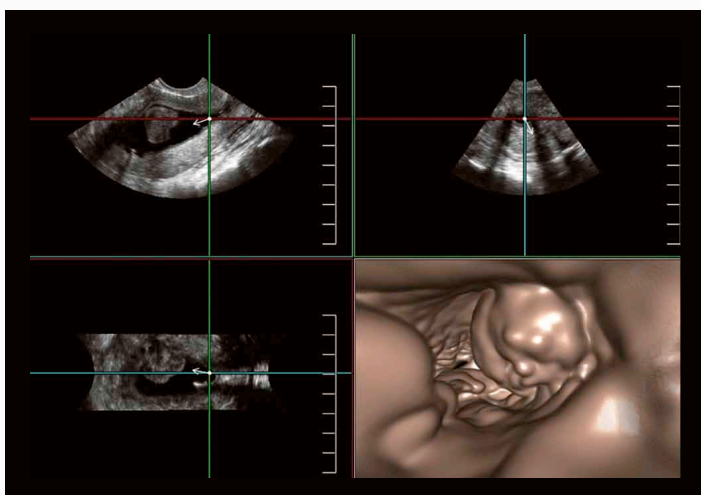


Fig. 1: Large intrauterine polyp.

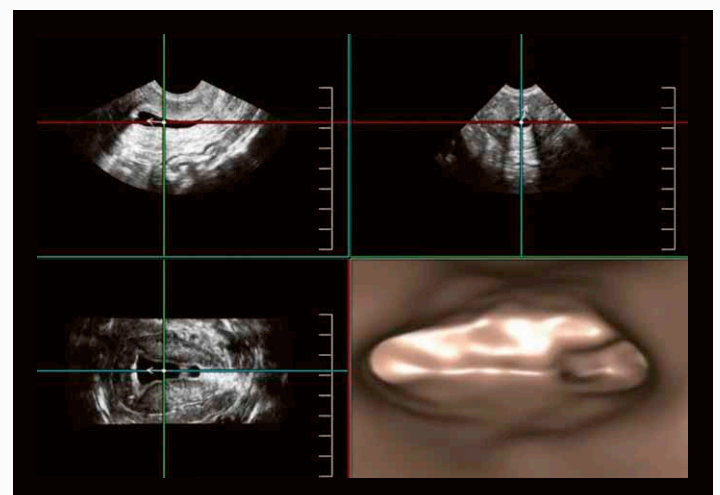


Fig. 2: Normal endometrial canal showing cornua and left fallopian tube. (Image courtesy of Bill Smith, CDS, London, UK.)

also capable of seeing relatively small fluid-filled structures, for example, dilated ducts in the breast that could assist in diagnosing intraductal papillomas. Another area for potential clinical application is vascular imaging, including venous structures, TIPS, the aorta and endostents.

Other areas with potential Fly Thru applications include obstetrics (OB), for early pregnancy cases and complex fetal anomalies, such as cleft palate and other facial anomalies. Another could be in the imaging of neonatal head, and a completely unique way of viewing hydrocephalus in infants. The GI tract is also a fairly obvious area, with the ability to visualize the common duct or pancreatic duct, the gall bladder or the gut. In the GU tract, hydronephrosis, stones, obstruction, transitional cell carcinomas (TCC) or even bladder lesions

have been nicely evaluated with Fly Thru. As we continue to investigate the clinical possibilities, we are excited by the opportunities this technology presents to improve patient diagnoses for many conditions. The following are specific clinical examples demonstrating Fly Thru's potential.

### Virtual Hysteroscopy

As stated previously, Fly Thru holds great clinical promise in performing virtual hysteroscopy. Two unique ways to use Fly Thru for virtual hysteroscopy include identifying a polyp and manipulating the image to view it from around the back for more accurate diagnosis (Fig. 1), and to assess the fallopian tubes (Fig. 2), which would be difficult to do with a traditional hysteroscopy.

### Virtual Ductography

Fly Thru for virtual ductography in the breast can show very small structures only millimeters in size and would lend itself well to the evaluation of intraductal papillomas (Fig. 3). No other modality can perform such imaging.

### Portal Venography

Veins are easily evaluated with Fly Thru. The portal veins are relatively immobile and therefore easy to image. In this example, Fly Thru is able to fly out into the periphery of this portal venous branch.

### Portal Vein Thrombosis

In another clinical example, the mass-like structure in the image actually represents an area of portal vein thrombosis (Fig. 4).

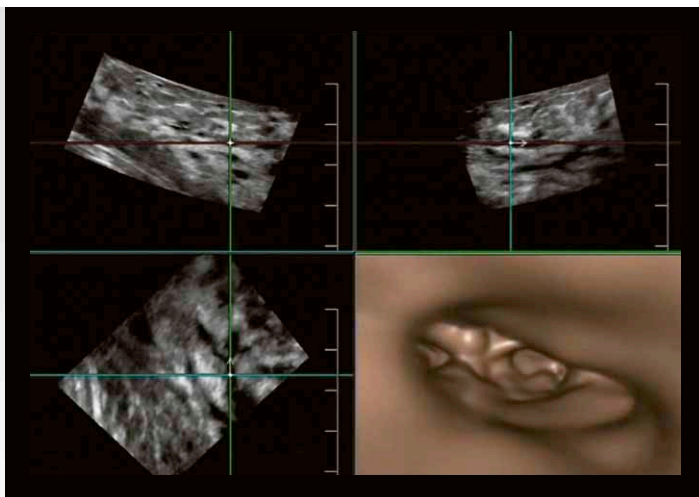


Fig. 3: Fly Thru of the breast demonstrating mild ductal ectasia.  
(Image courtesy of Dr. T Kurida, Kurida Clinic, Japan.)

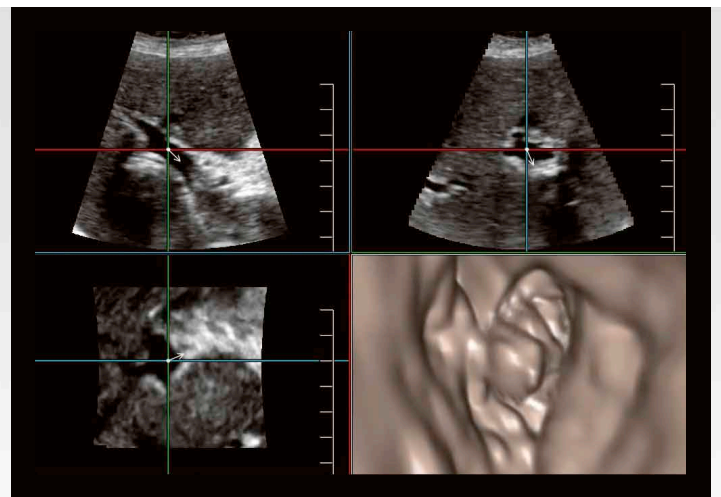


Fig. 4: Partial occlusive thrombosis of the portal vein.  
(Image courtesy of Dr. Kinkel, Duren Hospital, Germany.)

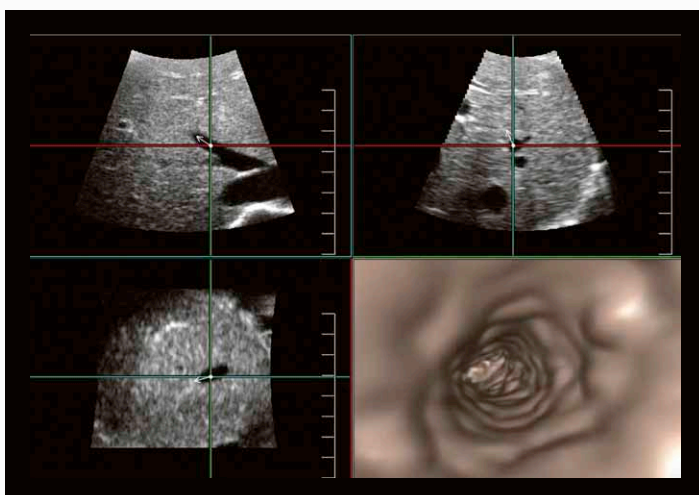


Fig. 5: Middle hepatic vein.

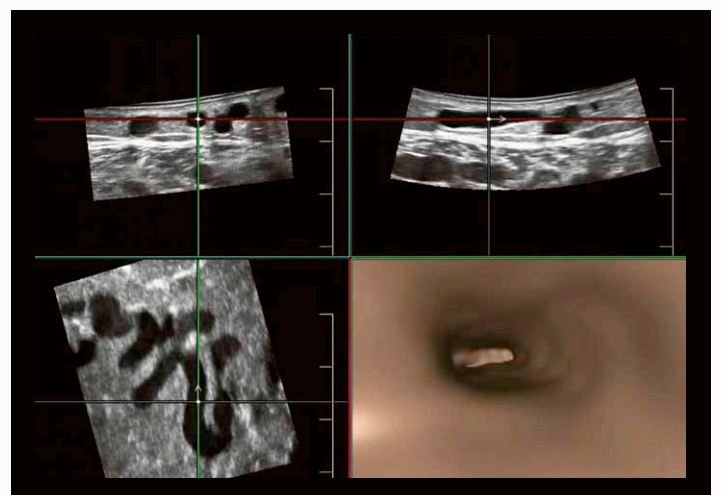


Fig. 6: Tortuous superficial varicose vein.  
(Image courtesy of Dr. J Hata, Kawasaki Medical University, Japan.)

### Hepatic Veins

The hepatic veins are often fairly large and easily interrogated with Fly Thru. Patients who have undergone a liver transplant may develop stenosis, and this could be a secondary way of identifying areas of stenosis (Fig. 5).

### Peripheral Veins

Fly Thru can also visualize walls and clots in the peripheral veins, both the deep and superficial (Fig. 6). 4D information provided by Fly Thru is superior to the traditional 2D cross-sectional ultrasound view, and for the first time ever, you can get an image of the true cross section space taken up by a clot.

### Transjugular Intrahepatic Portosystemic Shunt (TIPS)

Imaging of TIPS can be very challenging but is potentially made easier with Fly Thru. Most of the stenoses that affect the TIPS occur in the hepatic veins. This area may be difficult to image, and the only way to diagnose stenoses in this area currently is by looking for Doppler abnormalities, such as velocity elevation. In this particular case with Fly Thru (Fig. 7), a real-time image shows the anatomic structure of the TIPS and the ensuing hepatic vein after it, indicating a functioning shunt.

### Aorta

When imaging the aorta, there are a couple of technical challenges, most notably motion. Wall motion, if significant, can be problematic when

processing an image. With Fly Thru, clinicians can follow the aorta down and view the orifices of the vessels coming off of it, including the mesenteric and renal vessels, and the Iliacs distally. It is a unique application, similar to an IVUS but without performing an interventional procedure. This obviously makes it safer and easier for the patient (Fig. 8).

### Early OB

Fly Thru can also be used for imaging early pregnancies. In this instance, imaging is identical to a 3D sweep, so there is no added interrogation of these patients (Fig. 9).

### Gallstones

Fly Thru holds some potential for imaging solid masses that affect the gallbladder wall and provides a new and interesting perspective (Fig. 10).

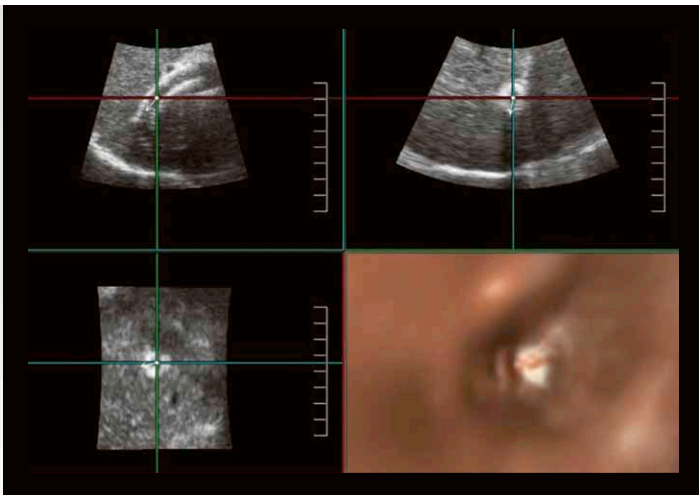


Fig. 7: Patent TIPS stent.

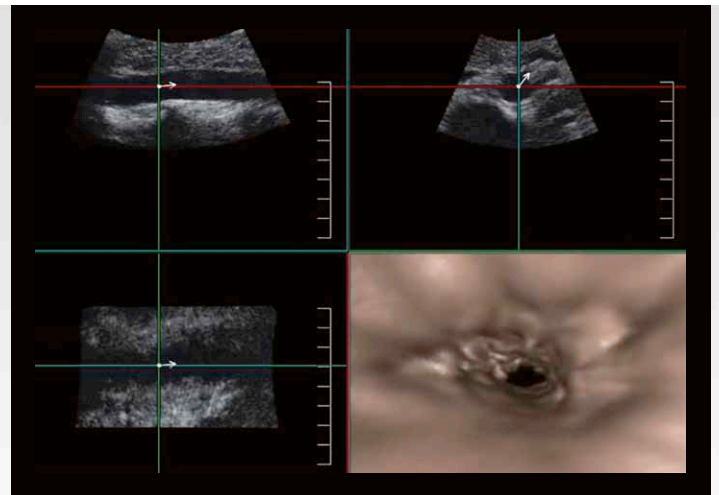


Fig. 8: Normal mid-abdominal aorta.

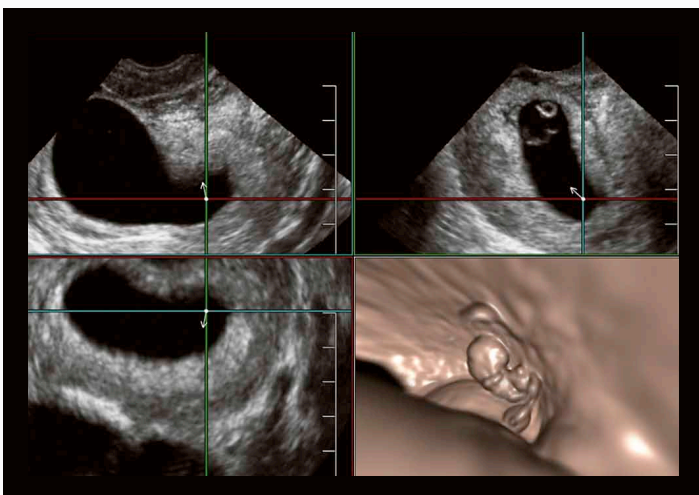


Fig. 9: Eight-week fetus.

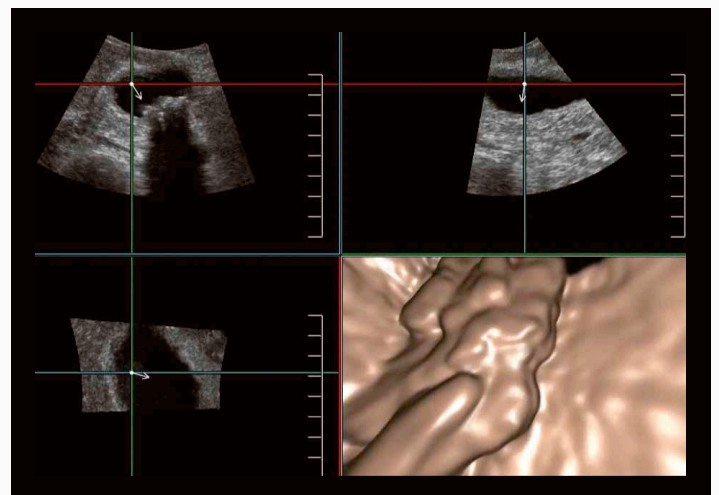


Fig. 10: Multiple small gallstones.

**Bile Duct Dilatation**

When imaging bile ducts, Fly Thru has the ability to show ductal dilatation (Fig. 11). Traveling down the duct and into the area around the pancreatic head or ampullary region, a mass like area can be seen on the horizon which actually represents an ampullary tumor that would be difficult to see with traditional imaging techniques.

**Dilated Small Bowel**

When it comes to imaging the bowel, Fly Thru produces images remarkably similar to virtual colonoscopy. In this small-bowel example of a patient with ileus, the valvulae conniventes can be viewed clearly using Fly Thru. Additionally, evaluating polyps or masses of the wall with Fly Thru has the potential to provide improved diagnoses (Fig. 12).

**Dilated Distal Ureter**

Structures at the distal ureter may also be evaluated using Fly Thru. This directed scan interrogates the ureter moving out of the bladder (Fig. 13), giving us the potential of directly visualizing occlusive kidney stones for the first time. Use bladder and urinary duct image here.

**Future Possibilities**

As we continue to evaluate the images produced by Fly Thru, there are some additional applications that hold great promise. One of those is using contrast with reversed polarity. Outside the U.S., contrast is often used with ultrasound. While this is off-label use in the U.S., contrast is extremely safe and clinically important. By taking a contrast image, for example, of the carotid artery, Fly Thru is able to reconstruct the lumen of the vessel.

In this image (Fig. 14), Fly Thru is able to travel from the common carotid into the internal carotid artery, providing unique images of the bifurcation. It is an interesting application which reverses the normal polarity of the image.

**Conclusion**

Fly Thru has the ability to yield more than just appealing images and could potentially improve the diagnoses of many diseases with ultrasound. The pictures produced are incredible and previously unseen in ultrasound, providing a unique form of imaging adaptation of 4D ultrasound. In addition, this provides a potentially powerful tool for communicating with a surgeon, an interventional specialist or the patient. For clinicians, this exciting new technology offers an untapped potential of clinical applications to improve patient care with ultrasound.

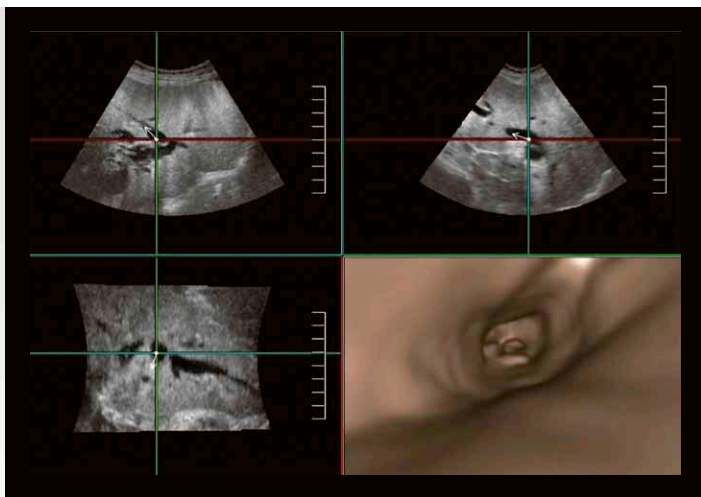


Fig. 11: Intrahepatic biliary ductal dilation. (Images courtesy of Dr. J Hata, Kawasaki Medical University, Japan.)

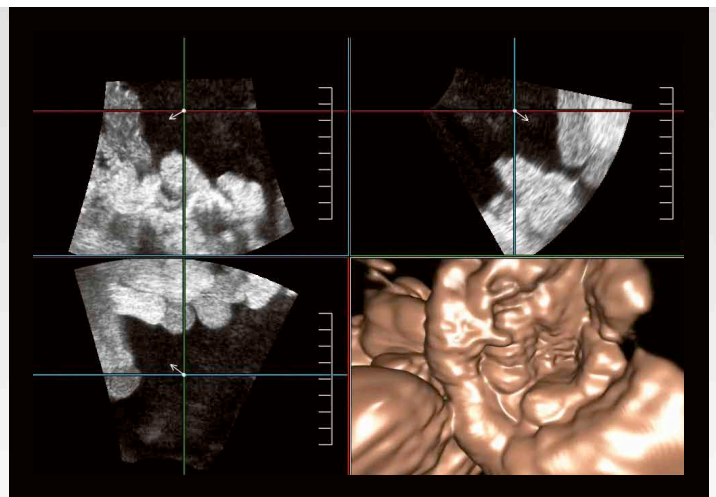


Fig. 12: Small bowel loops in abdominal ascites. (Images courtesy of Dr. J Hata, Kawasaki Medical University, Japan.)

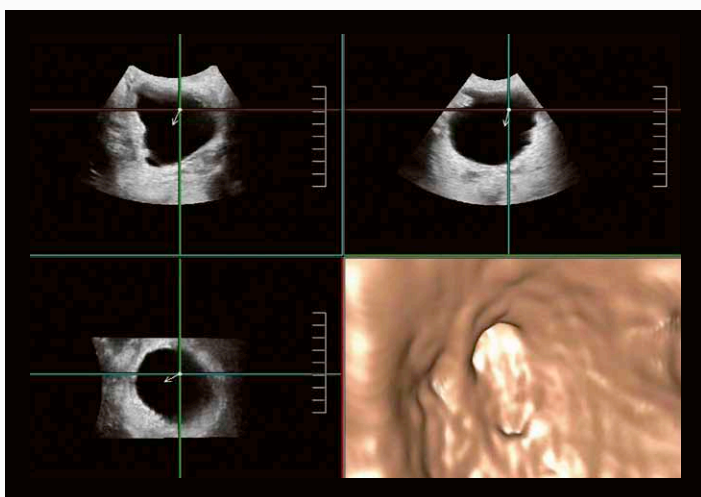


Fig. 13: Dilated distal ureter.

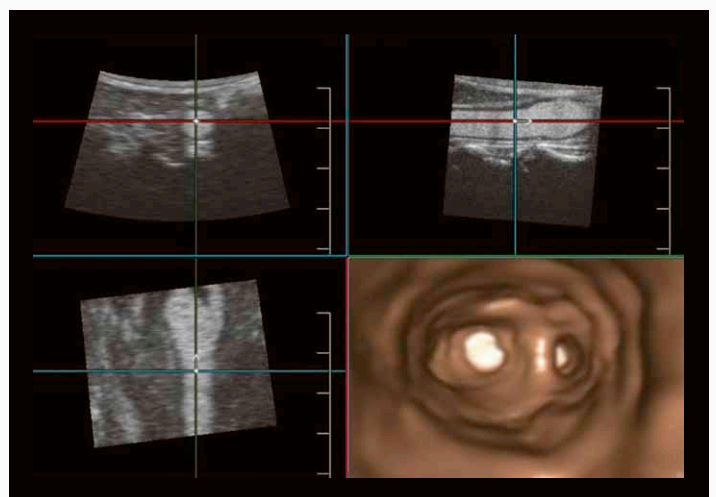


Fig. 14: Contrast enhanced image of the carotid bifurcation. (Images courtesy of Dr. J Hata, Kawasaki Medical University, Japan.)

**TOSHIBA MEDICAL SYSTEMS CORPORATION**

©Toshiba Medical Systems Corporation 2012 all rights reserved.  
Design and specifications subject to change without notice.  
12/2012 MWPUL0019EUC  
Printed in Europe

[www.toshiba-medical.eu](http://www.toshiba-medical.eu)



---

**ULTRASOUND CT MRI X-RAY SERVICES**