

Cover photo: Toshiba Viamo portable ultrasound system at the Glastonbury Pyramid stage. Pictured from left to right: Radiologists Dr. Mark Regi and Dr. Rob Hawkes, Shane Hanlon (Clinical Applications Specialist Toshiba Medical Systems) and radiologists Dr. Rebecca Duerden and Dr. Mark Hamilton.

TOSHIBA
Leading Innovation >>>



Portable Ultrasound Headlines at Glastonbury Festival

Dr. John Mark Regi BSc MBBS MRCS FRCR FHEA
Affiliated to Severn School of Radiology, Bristol, United Kingdom

Shane Hanlon, Clinical Applications Specialist
Toshiba Medical Systems Ltd, Crawley, United Kingdom

Viamo
performance to go

TOSHIBA MEDICAL SYSTEMS CORPORATION

©Toshiba Medical Systems Corporation 2009 all rights reserved.
Design and specifications subject to change without notice.
09/2009 TCSUS0002EC.EU

www.toshiba-medical.eu



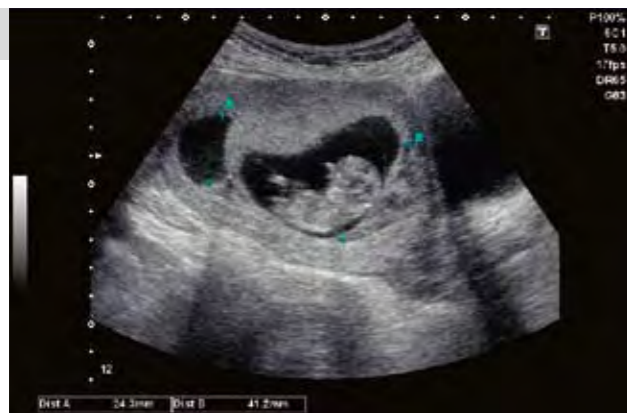ULTRASOUND CT MRI X-RAY SERVICES

Printed in Europe

As the summer months peak, 200,000 festival lovers descend on Worthy farm in Somerset for the largest music festival of the year. Most people's vision of the Glastonbury Festival includes muddy fields, endless rows of tents and an enormous diversity of headline acts. Few contemplate the logistical challenges of providing high quality health care to a population equivalent to that of a city such as Norwich or Newcastle. Every year for the last 25 years Festival Medical Services (FMS) has provided a team of doctors and nurses to look after this transient crowd of festival goers. Each year FMS supplies 600 staff and sees close to 4000 patients over the six days of Glastonbury, almost double the figures of most emergency departments in the UK. The patients suffer a variety of mishaps from trivial insect bites and sprains through to potentially life threatening conditions. This year there were three cases of Swine Flu, two Glastonbury babies and one death.

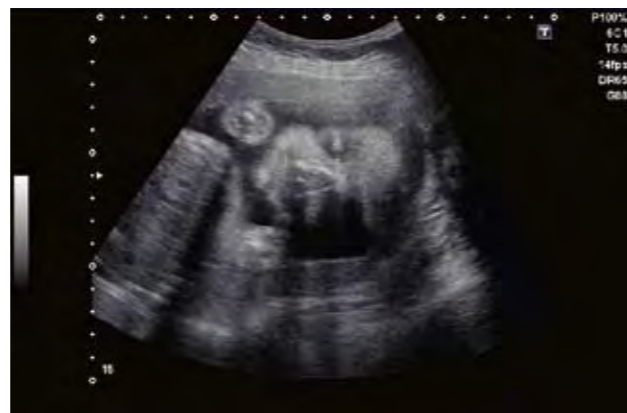Musculoskeletal injuries are the most common presentation and for the last two years FMS has offered a fully digital radiography service. Approximately 150 X-ray examinations were carried out and digital images of positive X-rays were copied to CD-ROM to prevent duplication of radiological examinations at fracture clinics. This year in partnership with Toshiba Medical Systems, FMS expanded to provide a 24 hour on-call ultrasound service. This was provided by a team of six radiologists of different specialties using the brand new pre-released version of Toshiba's Viamo portable ultrasound system. The system's array of probes allows for a wide range of examinations including abdominal, gynaecological, musculoskeletal and cardiac imaging. In addition to the team and scanner, application support was on hand to help exploit the Viamo's potential.

Fig. 1



10-week live intrauterine pregnancy with an adjacent 24 mm subchorionic bleed

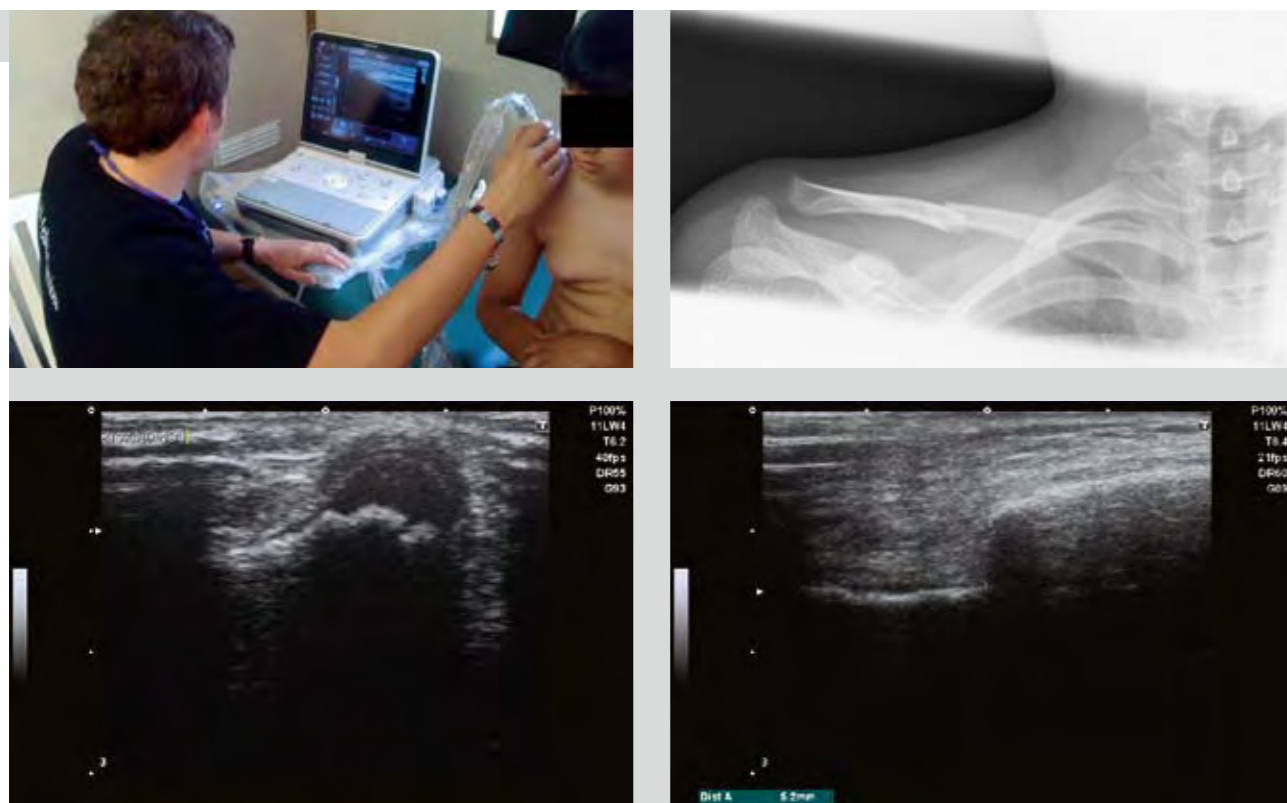
Fig. 2



Third-trimester scan for confirmation of viability demonstrating the foetal face

Justification for on-site imaging is to make diagnoses to support valid transfers to a hospital and prevent unnecessary admissions to the busy on-take hospitals supporting the festival. The team of radiologists encouraged the FMS emergency doctors to request ultrasound investigations in the same fashion as they would do in their normal practice. There were twenty requests for ultrasound investigation and twelve scans performed. Many of the ultrasound requests were for pregnant patients with suspected miscarriage (Fig. 1) or third trimester patients (Fig. 2) with anxiety due to lack of recent foetal movement. The ability to image these patients for confirmation of foetal viability eased patient anxiety and prevented unnecessary transfer.

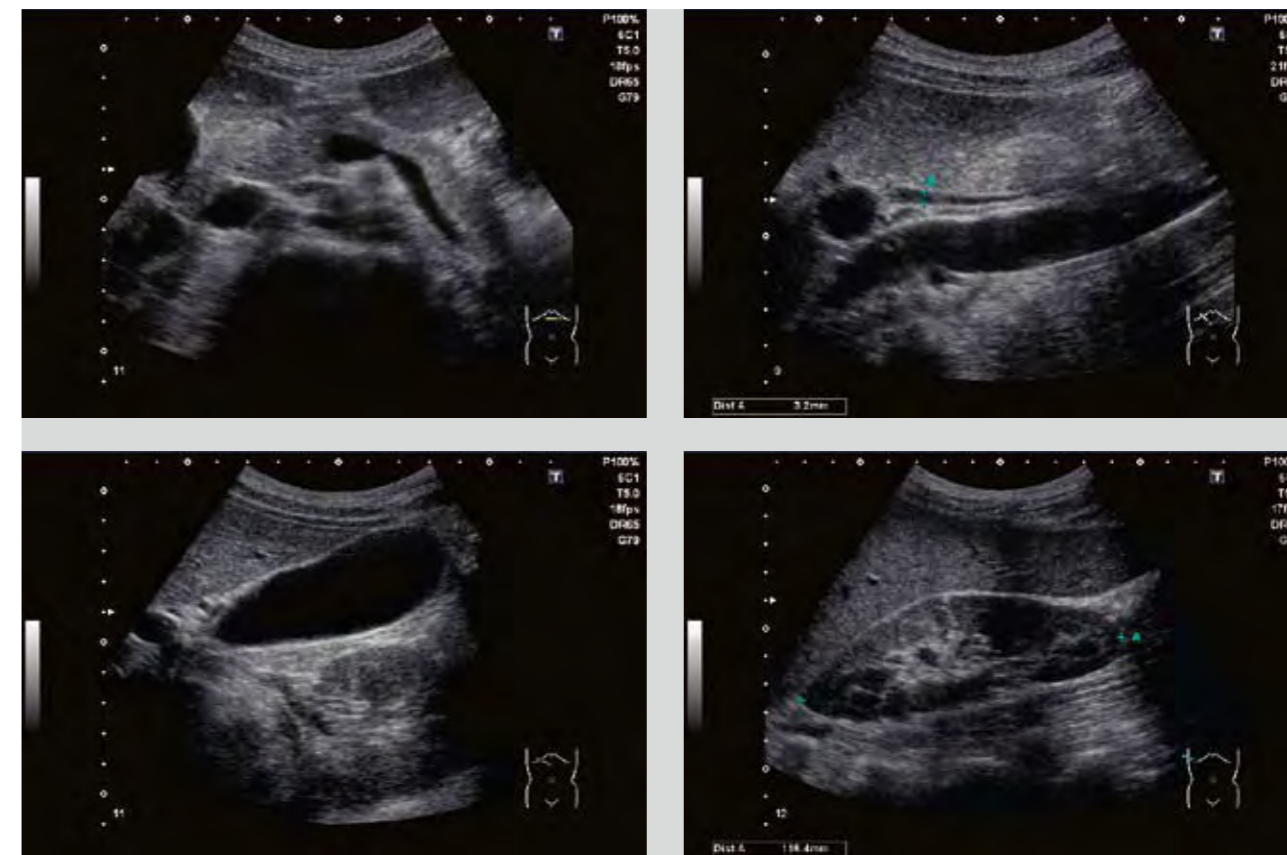Fig. 3



Ultrasound of right shoulder demonstrating acromioclavicular joint effusion with mid-shaft clavicle fracture and corresponding X-ray

Examinations were also performed for pyelonephritis, acute abdominal/pelvic pain and musculoskeletal injuries. Figure 3 shows the first ultrasound examination of Glastonbury 2009. A 12 year old male presented with a history of trauma to the right shoulder and a decreased range of movement. Ultrasound examination diagnosed a mid shaft clavicular fracture and associated acromioclavicular joint effusion. The patient was treated conservatively and returned to the festival. The Viamo also proved useful for foreign body localisation and the identification of ligament and tendon injuries.

Fig. 4



Ultrasound of the upper abdomen. Images show the usual suspects for RUQ pathology: pancreas, distal common bile duct, gall bladder and right kidney

In a typical fashion to many emergency department presentations, a 29 year old female attended with a 24 hour history of right upper quadrant pain. The ultrasound examination excluded renal obstruction and significant pathology which requires surgery. After urine analysis the patient was treated for right sided pyelonephritis. A different case of left flank pain demonstrated a localised large bowel wall thickening and probable diverticulitis.

The Viamo combined all the advantages of a portable ultrasound system with the diagnostic quality, comfort and ease of use of a premium cart-based system. The Viamo's 15 inch built-in touch control screen demonstrated intuitive functions which our radiologists found easy to use. It provided excellent resolution imaging which gave the radiology team confidence in their diagnoses. Captured images and video clips were transferred directly to USB memory stick in either DICOM or Windows format. Each of the patients examined with ultrasound were offered copies of their clinical images on CD-ROM with the associated radiological report. This prevented further re-imaging and provided documented evidence of the clinical episode.

The ultrasound service at Glastonbury Festival made a positive impact in the treatment and potential hospital transfer in three quarters of the patients examined. Whilst examination should never delay the transfer of a seriously unwell patient it changed the management and prevented many unnecessary hospital admissions.